

BONE SCINTIGRAPHY

Dr.E.Gharepapagh
Nuclear Medicine



COMMON RADIOTRACER:

^{99m}Tc -MDP

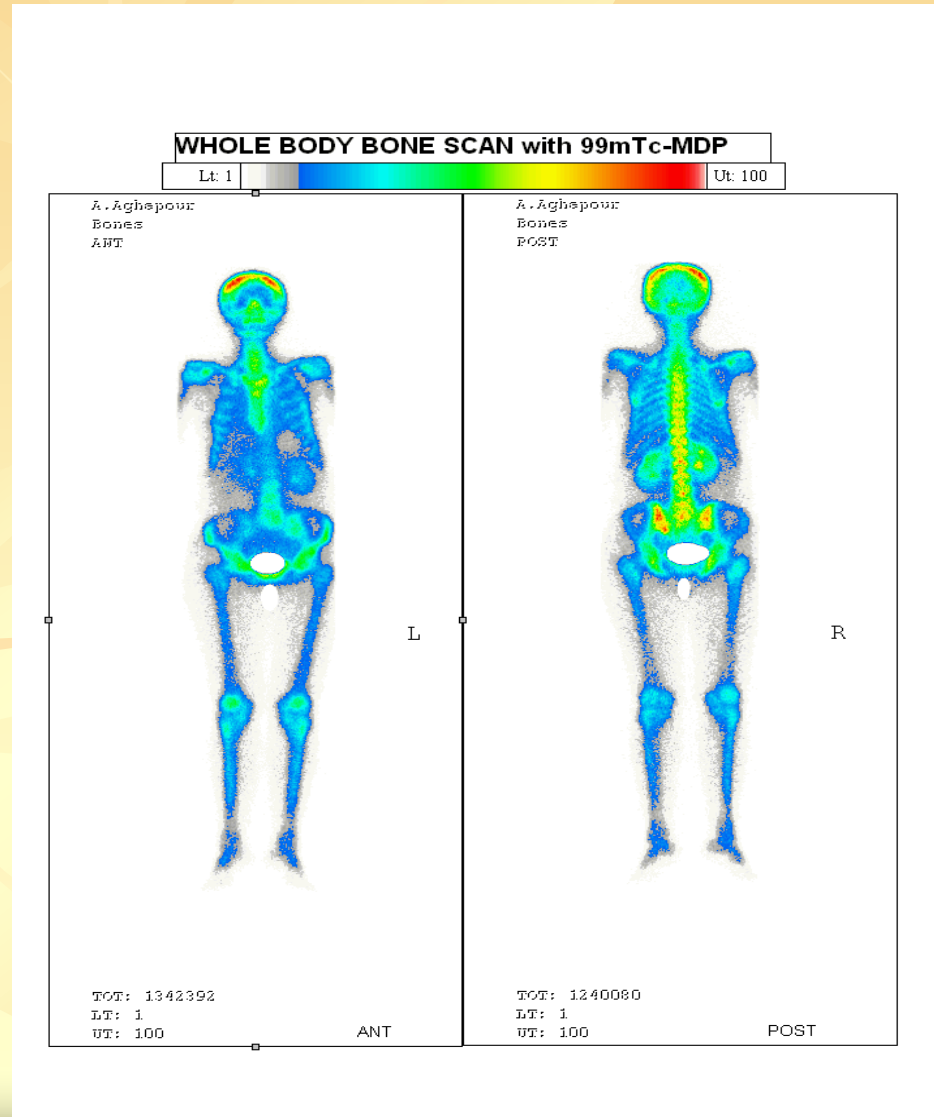


INDICATIONS

- SKELETAL METASTASIS
- PRIMARY BONY TUMORS
- INFECTION(OSTEOMYELITIS)
- AVN
- SKELETAL PAIN
- TRAUMA(STRESS, OCCULT & MULTIPLE FX)
- METABOLIC BONE DISORDERS

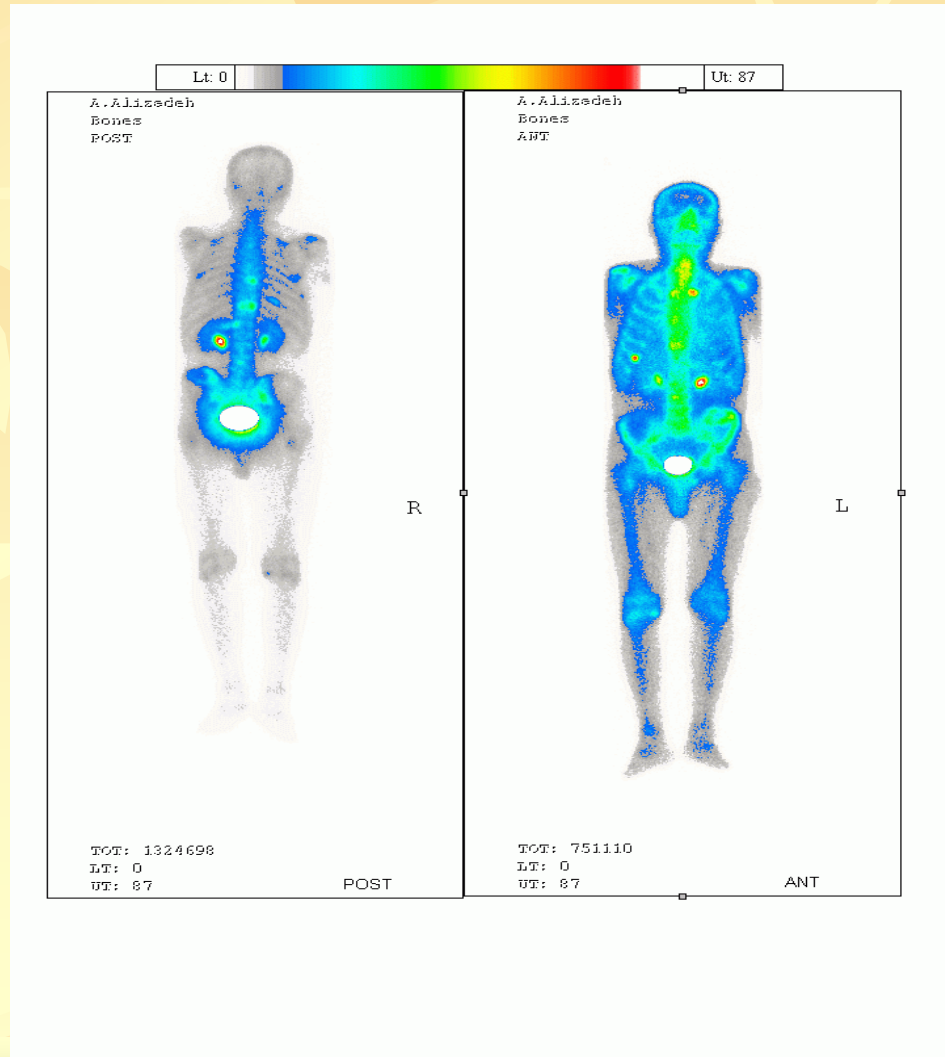


NORMAL BONE SCAN



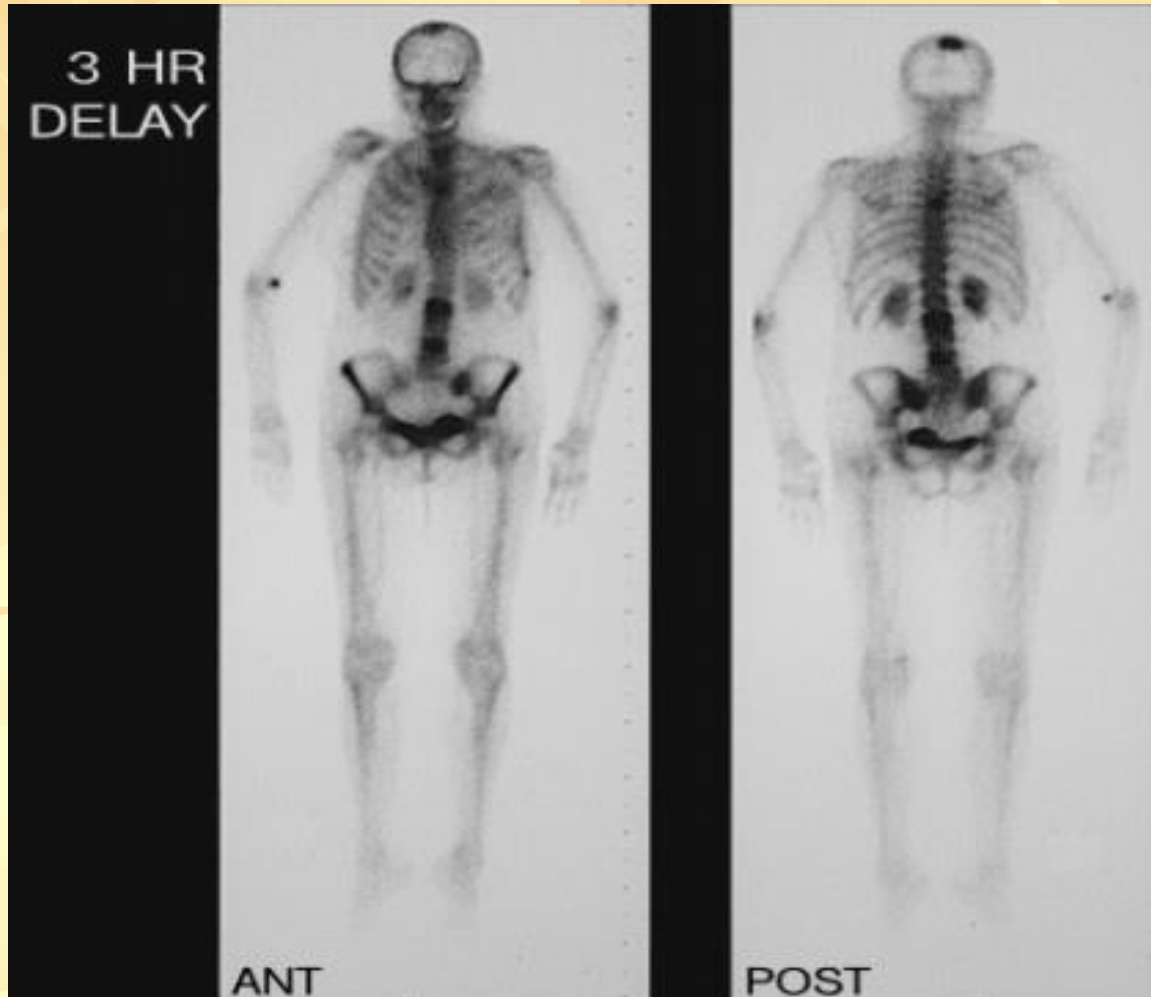
SKELETAL METASTASIS

■ LUNG CANCER

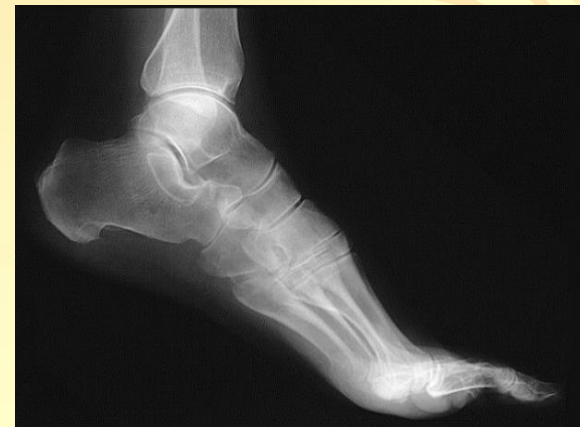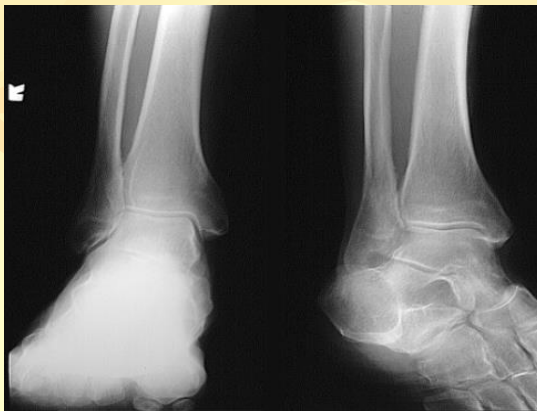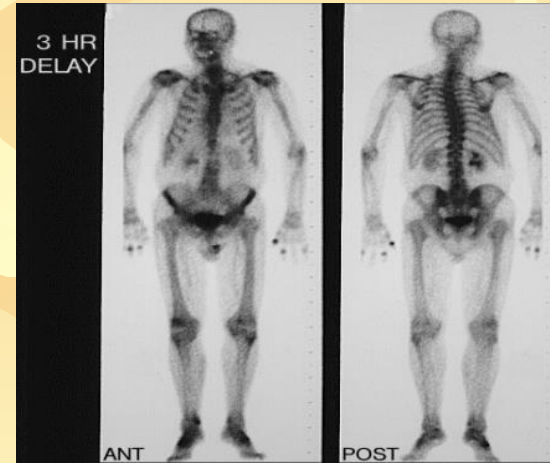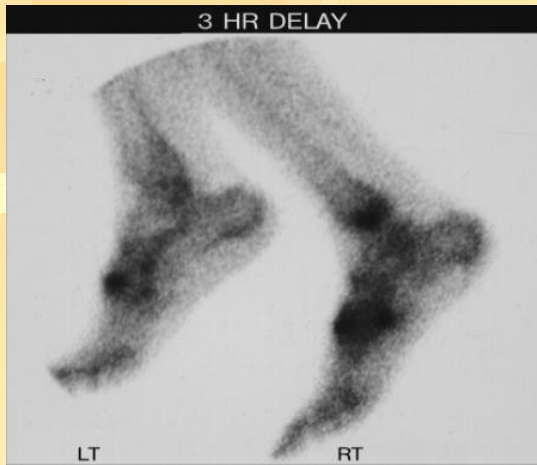


SKELETAL METASTASIS

- BREAST
CANCER



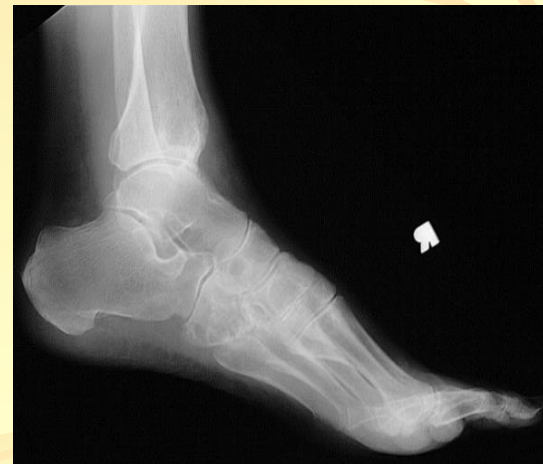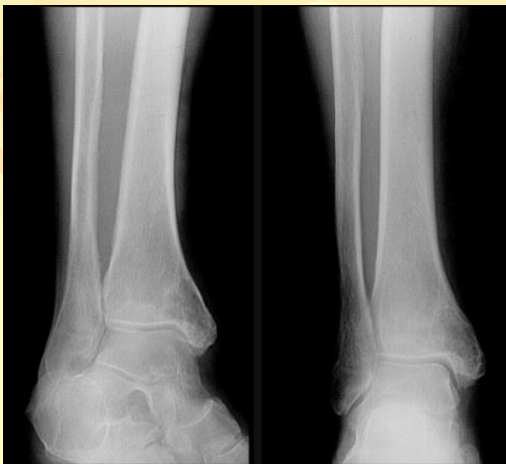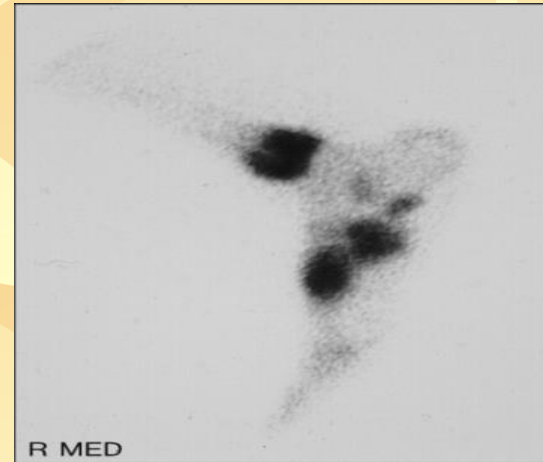
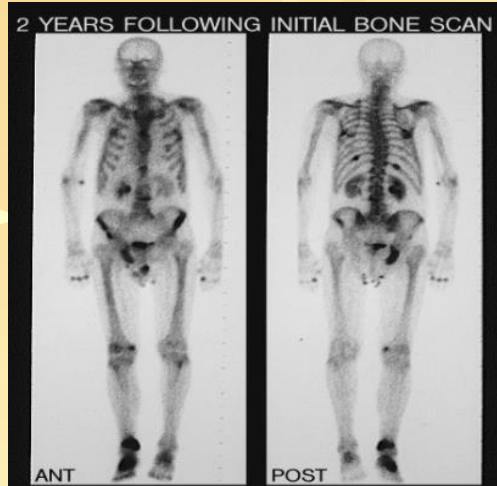
SKELETAL METASTASIS



- Prostatic cancer(early phase):normal x-ray



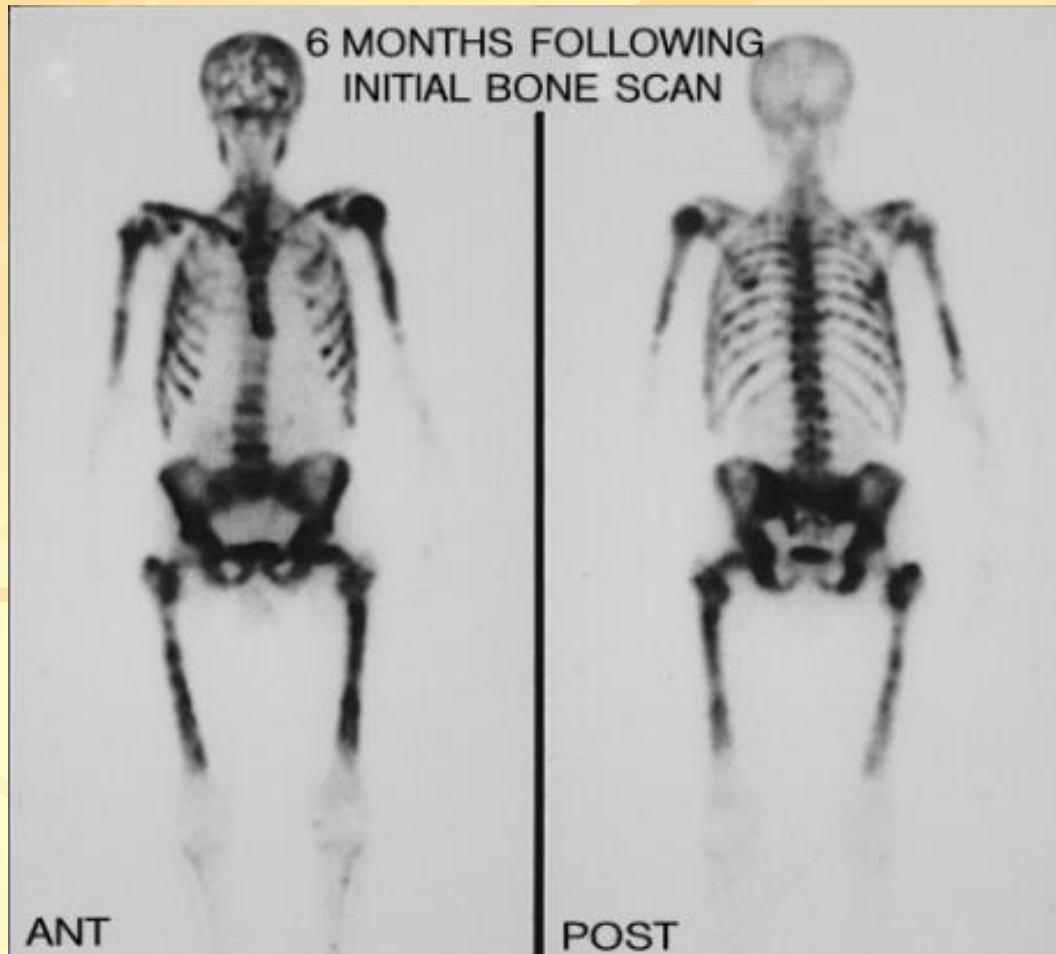
SKELETAL METASTASIS



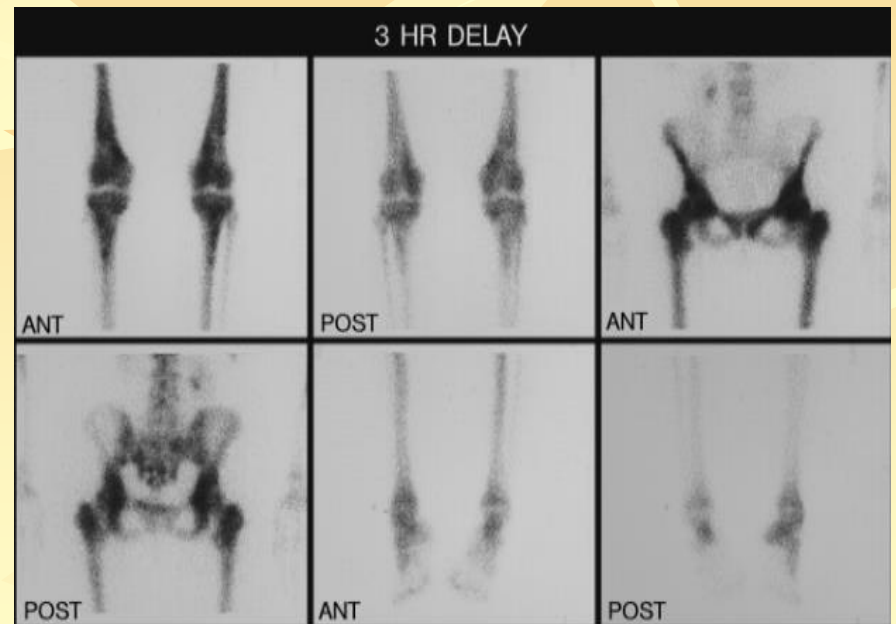
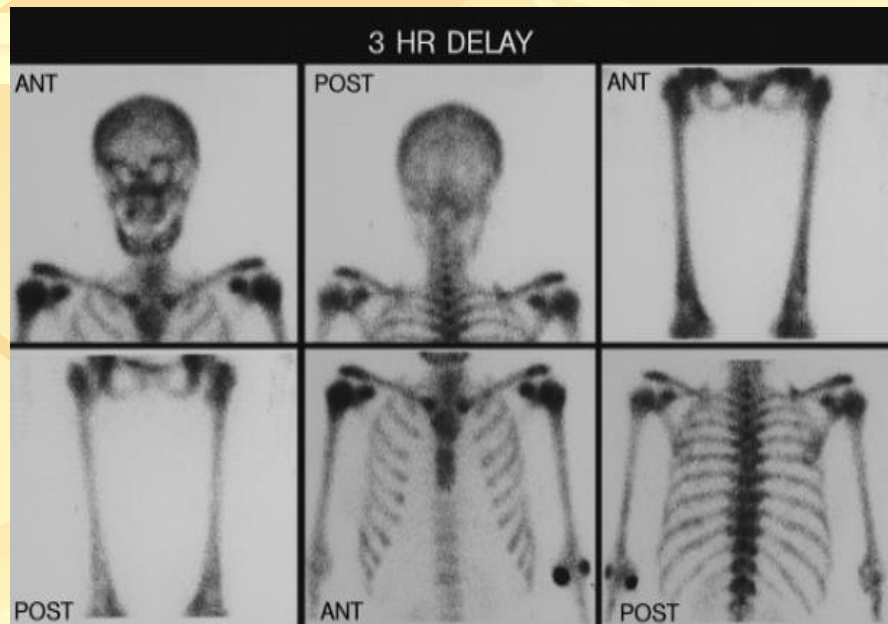
- Two years later:lytic lesions on x-ray



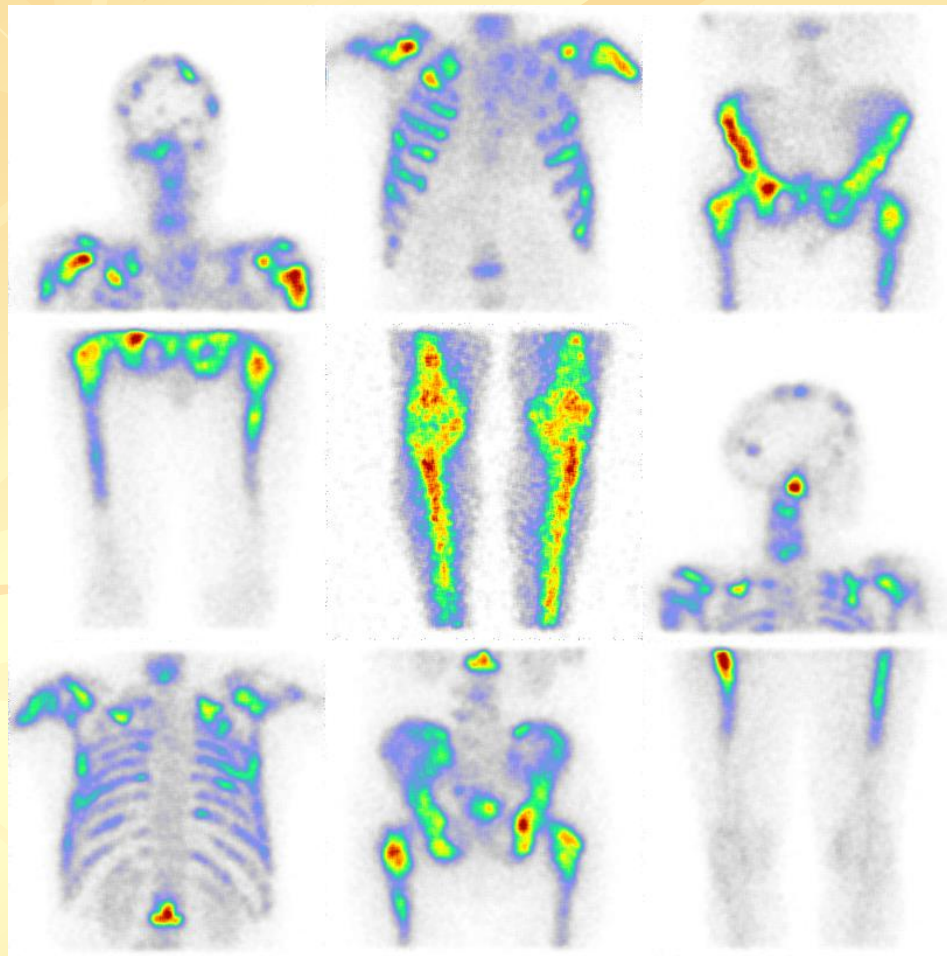
SUPER SCAN (PROSTATE CA.)



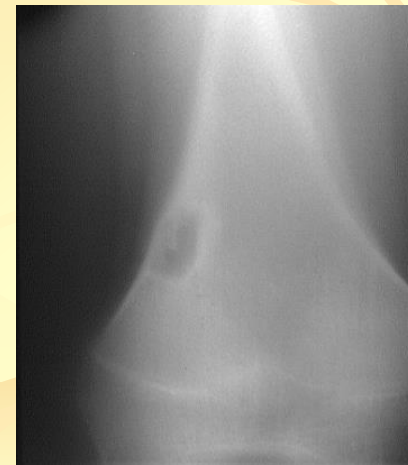
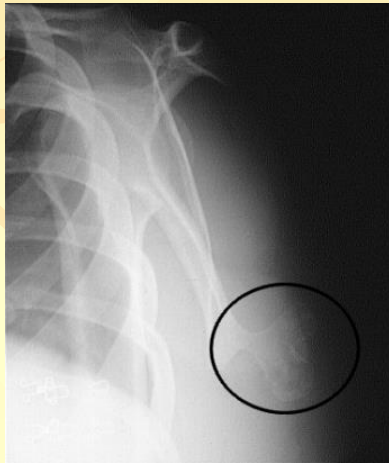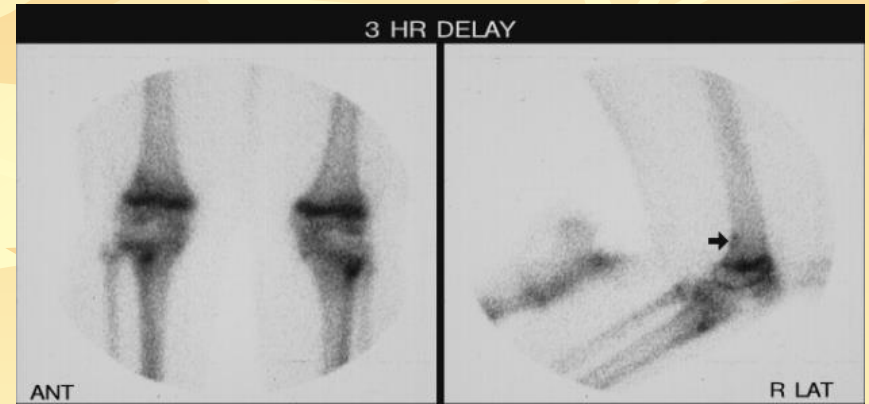
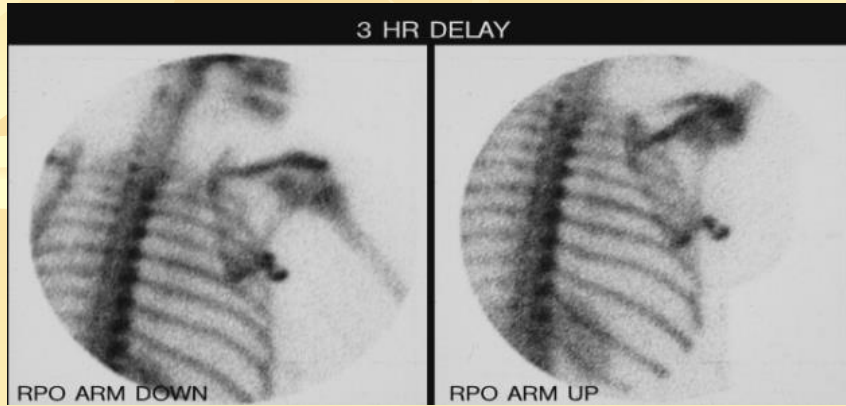
SUPER SCAN (BREAST CA.)



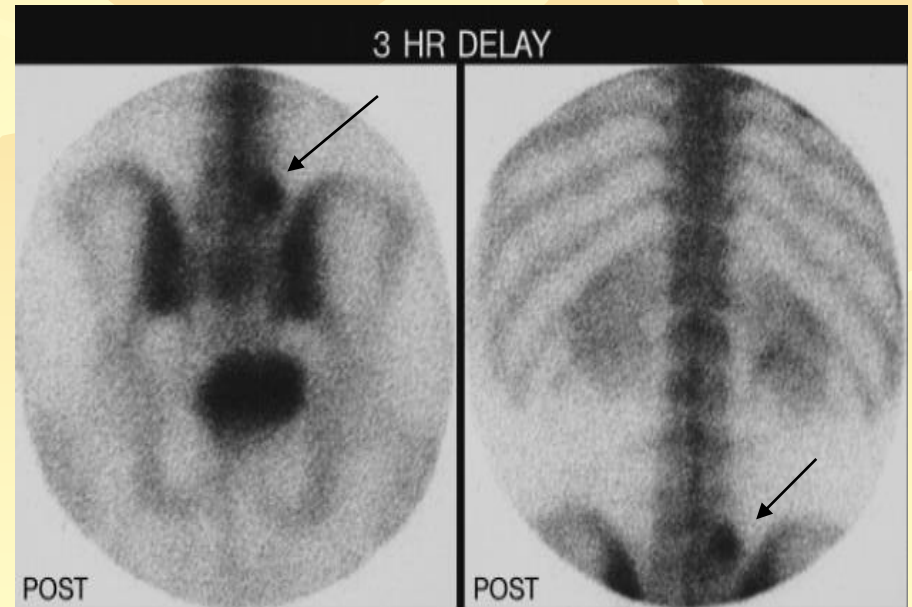
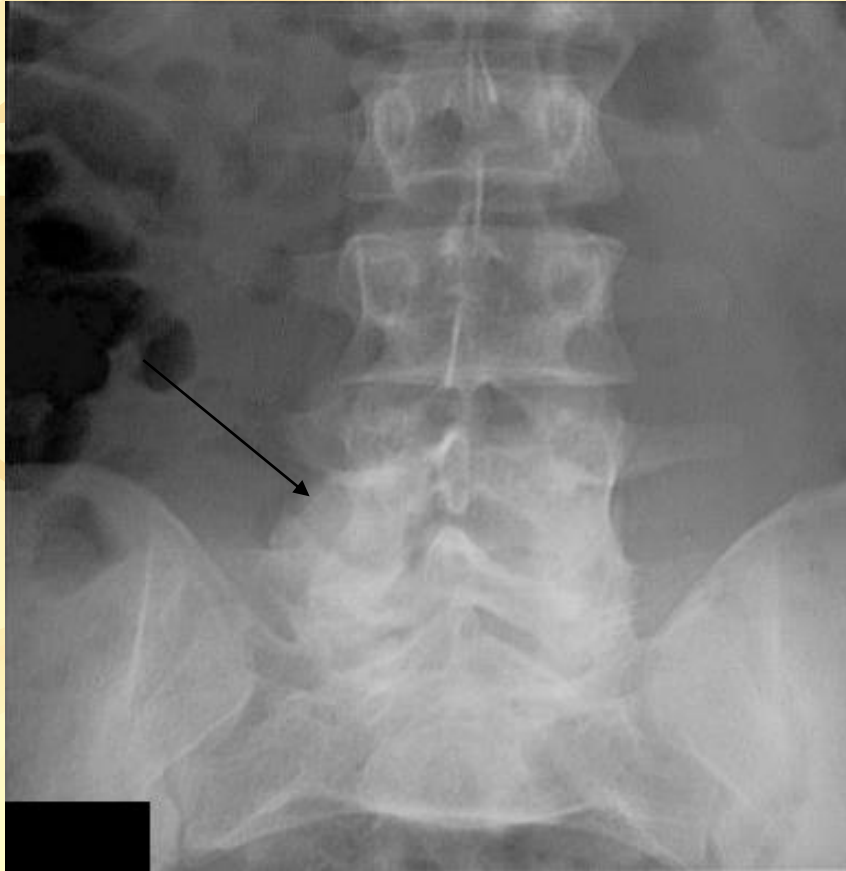SUPER SCAN (PROSTATE CA.)



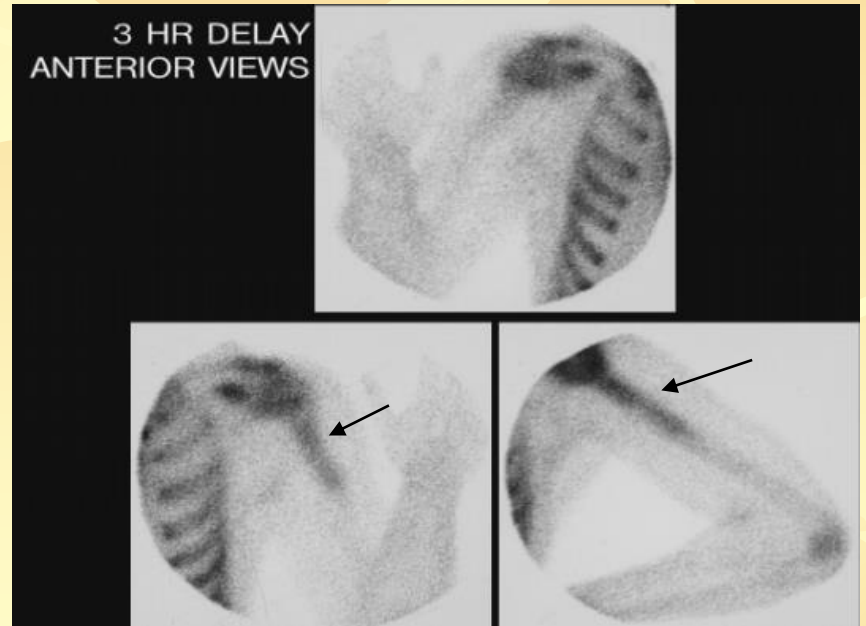
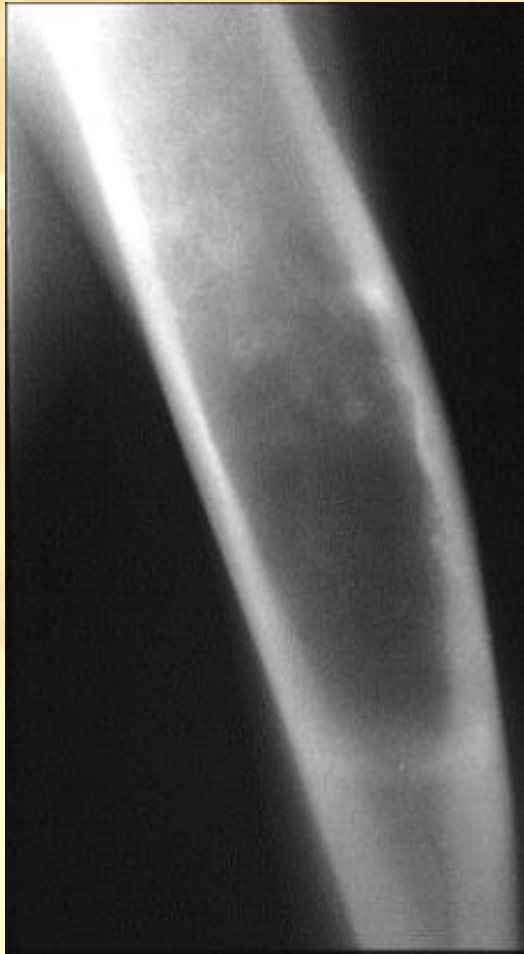
OSTEOCHONDROMA OF THE Rt.SCAPULA & NON-OSSIFYING FIBROMA OF DISTAL Rt.FEMUR



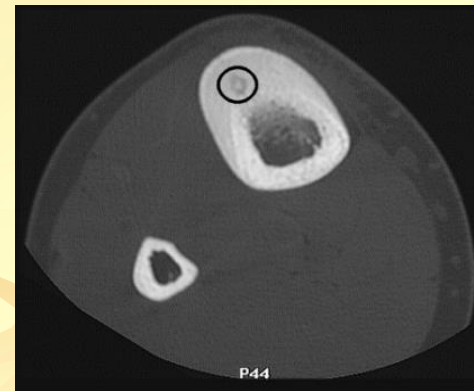
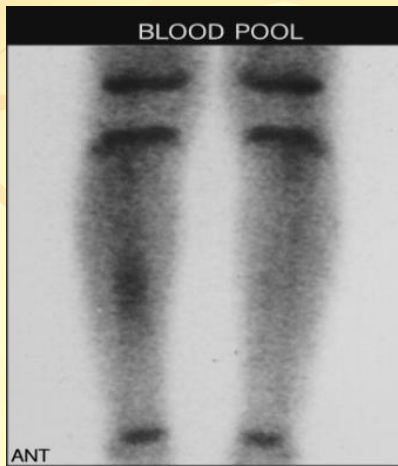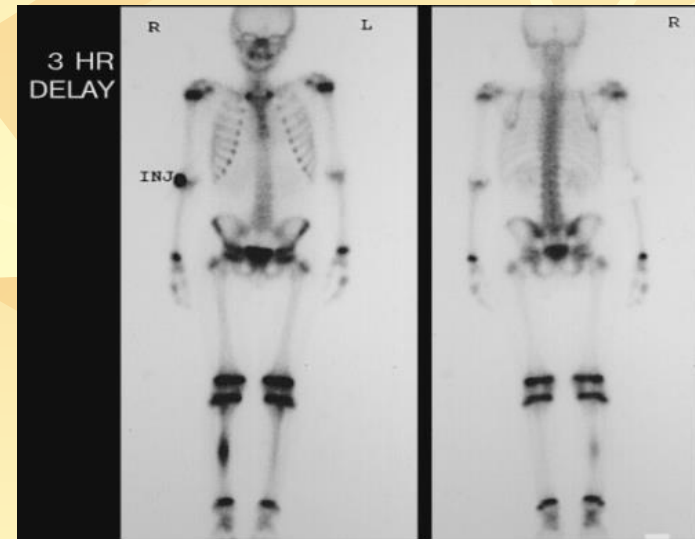
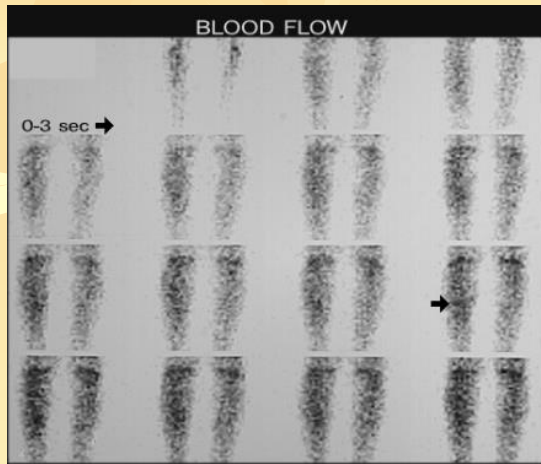
OSTEOBLASTOMA (Rt.L5 pedicle)



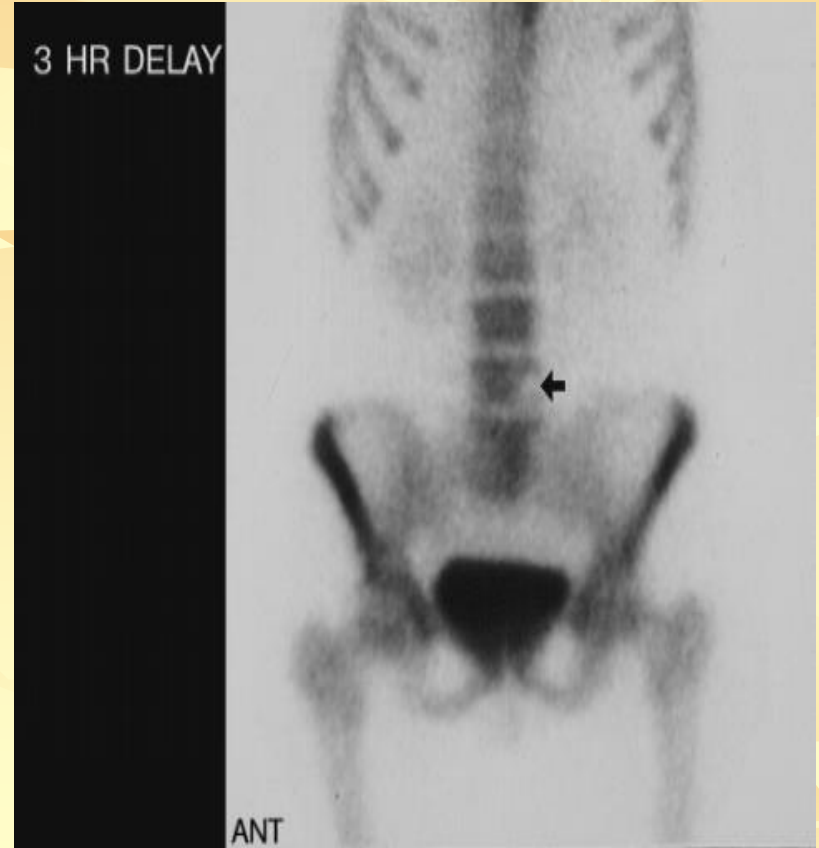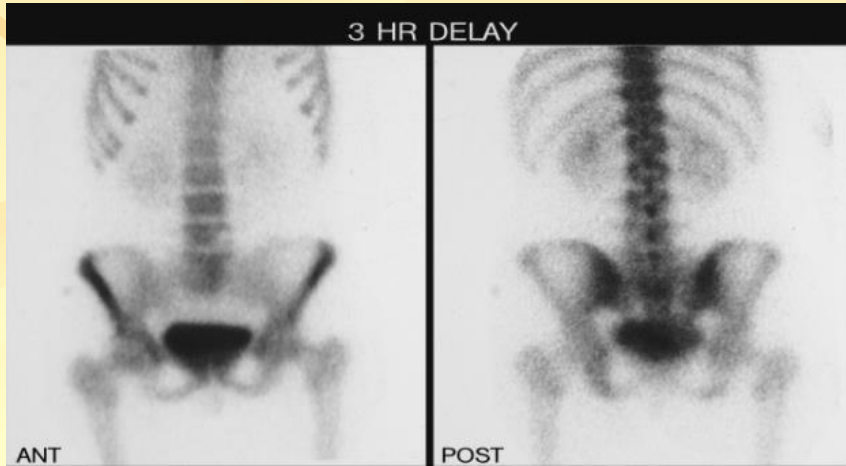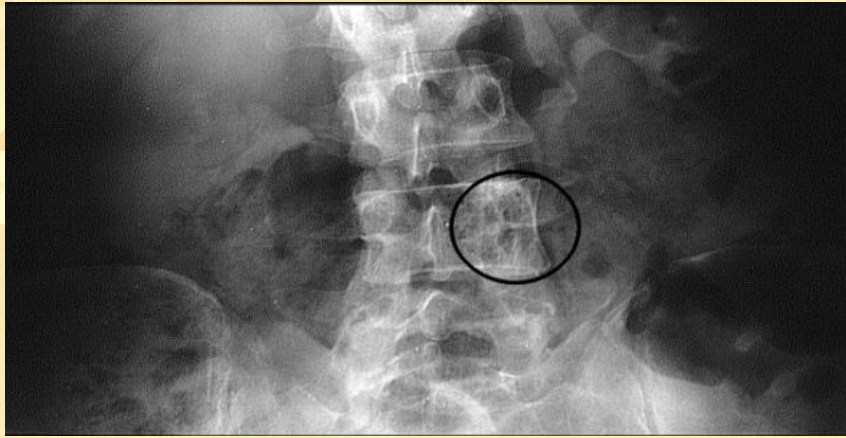
UNICAMERAL BONE CYST



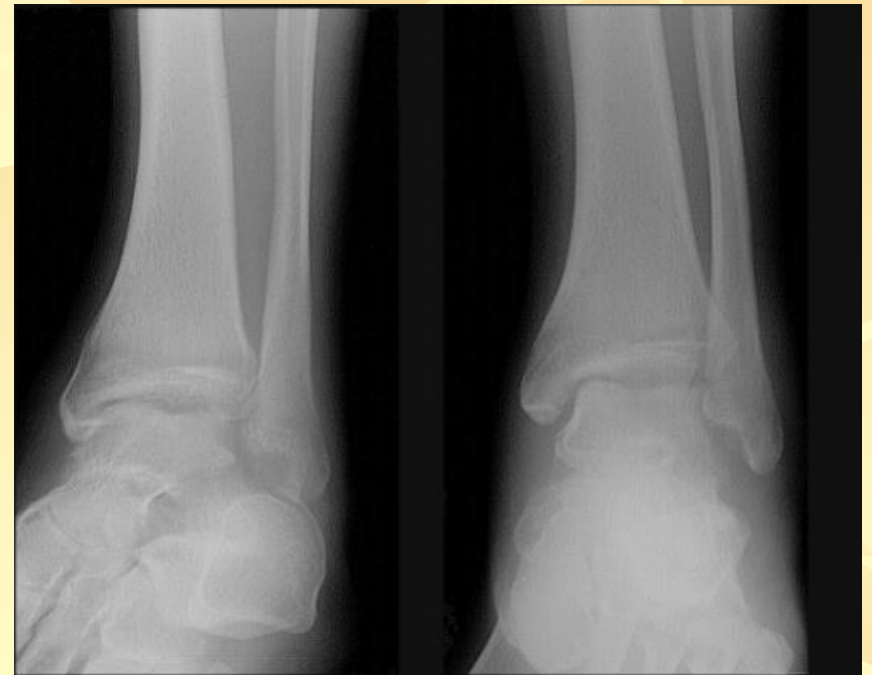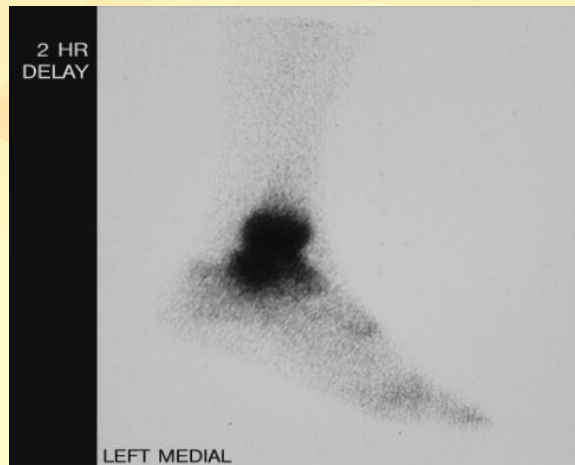
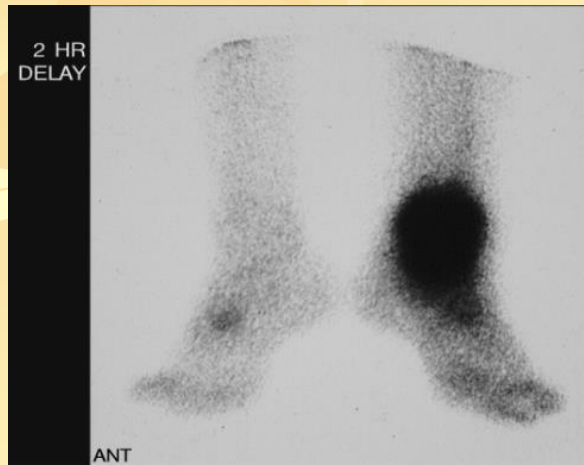
OSTEOID OSTEOMA



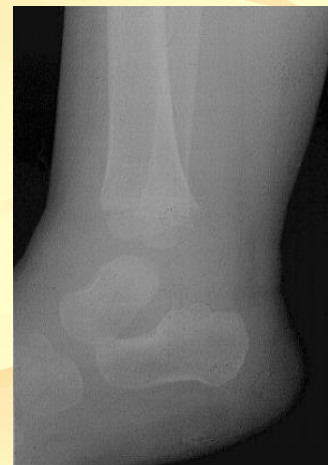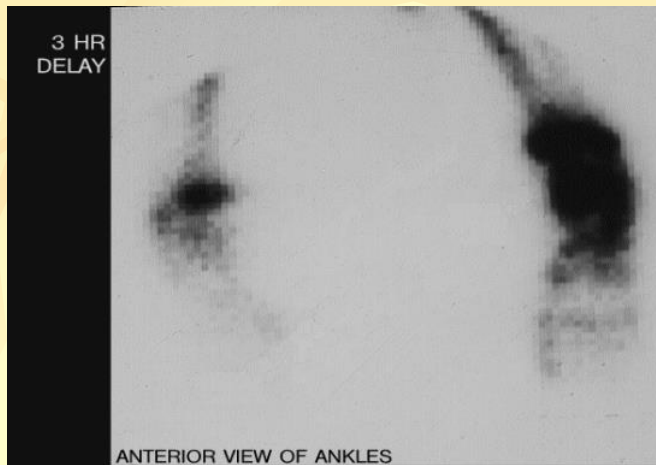
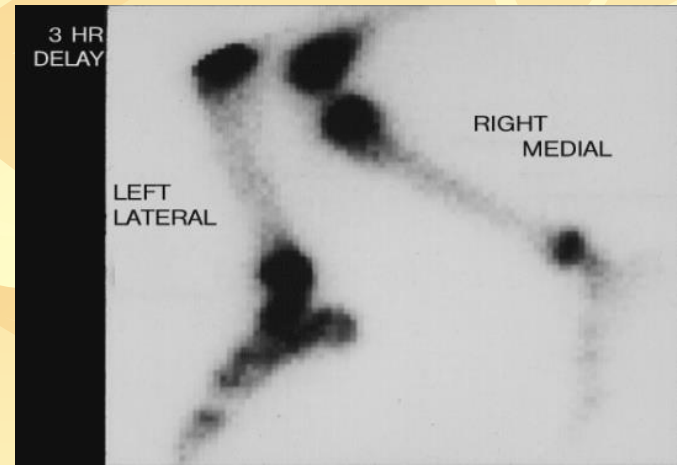
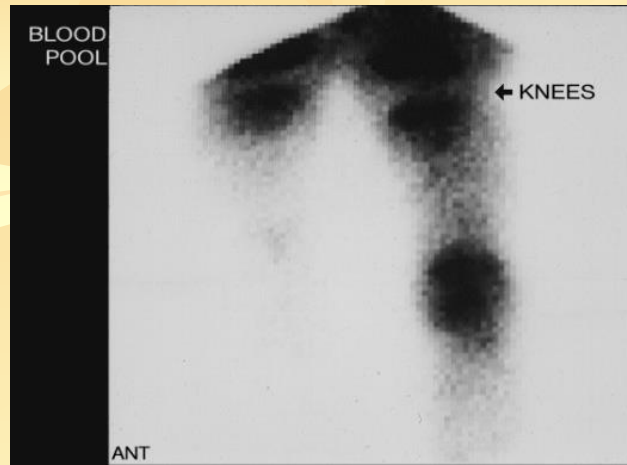
HEMANGIOMA of the L4



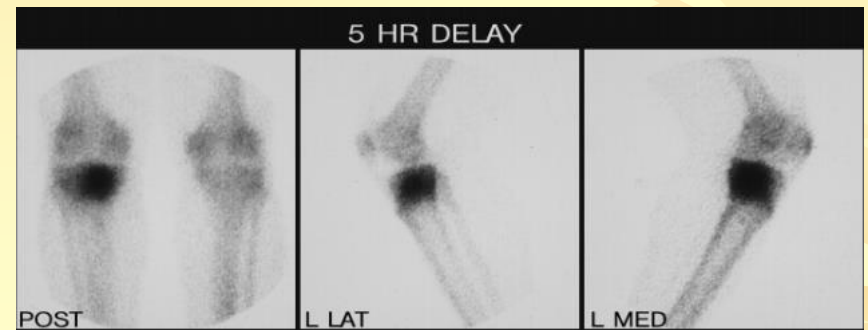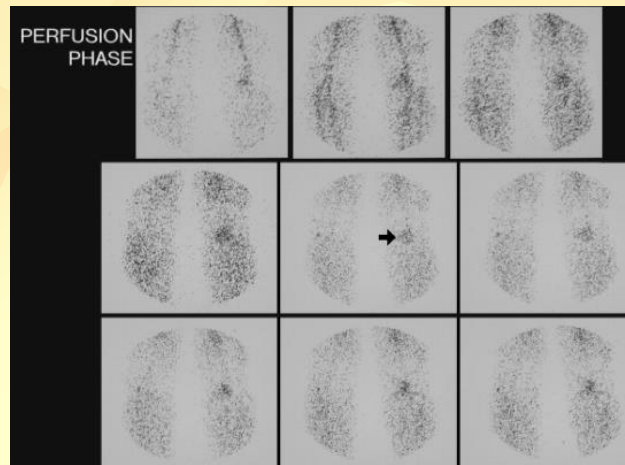
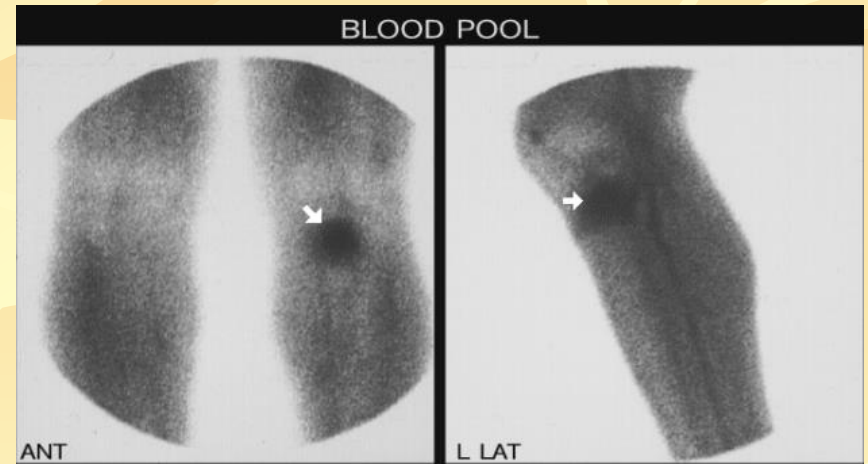
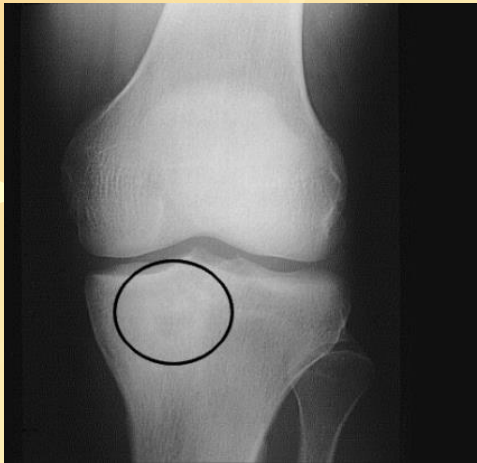TUBERCULOUS ARTHRITIS



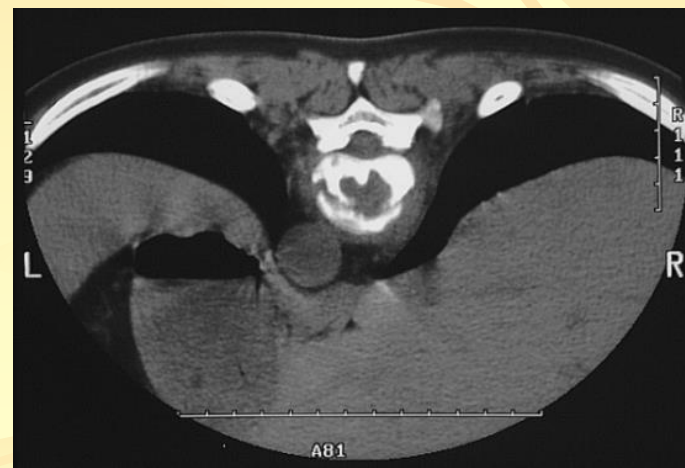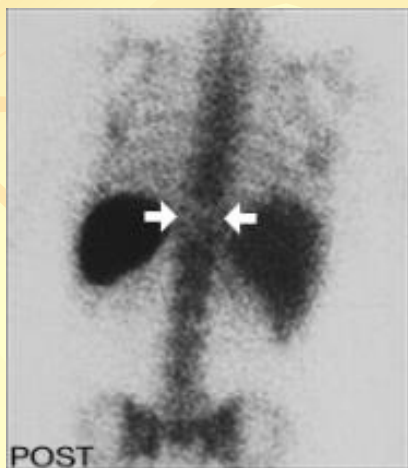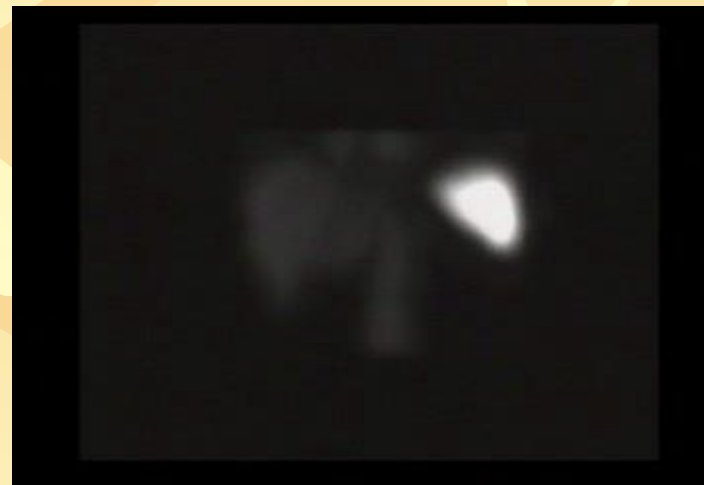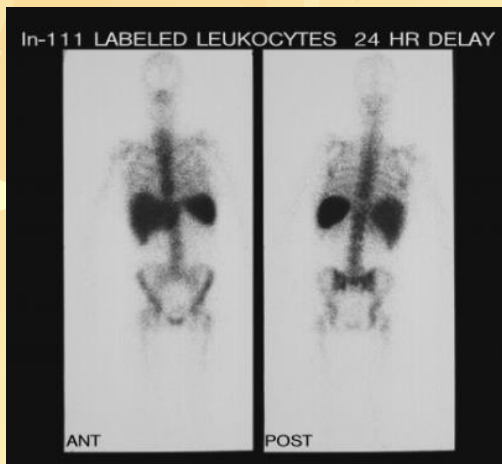
SEPTIC ARTHRITIS(Lt.ankle)



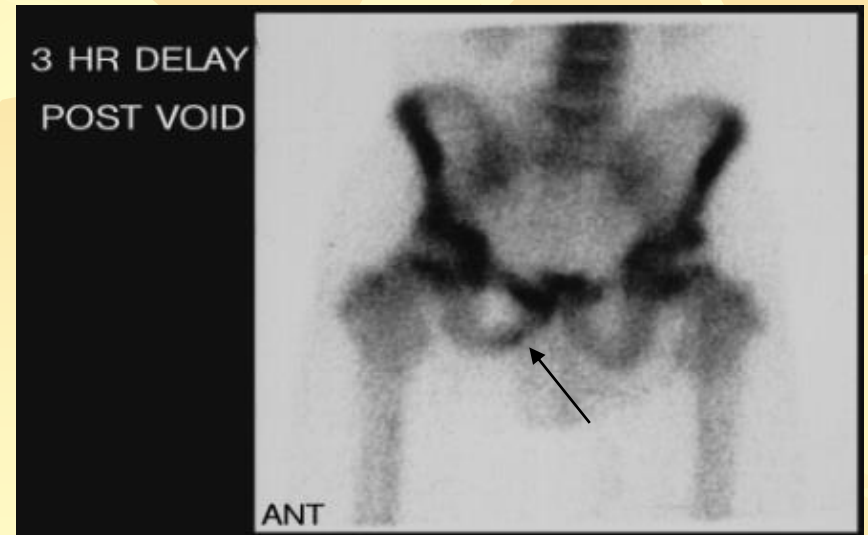
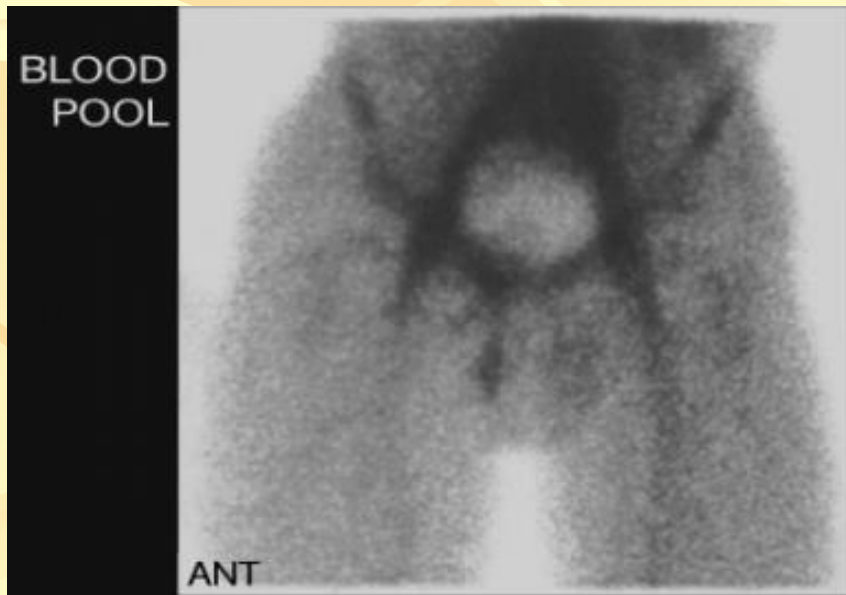
BRODIE'S ABSCESS



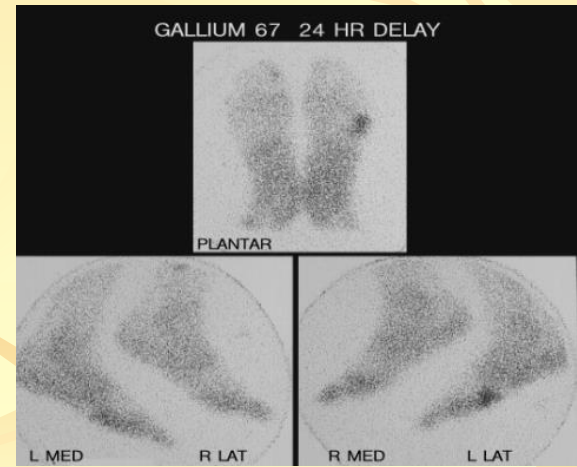
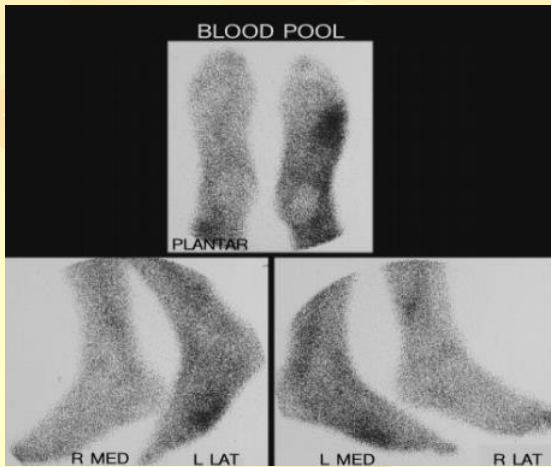
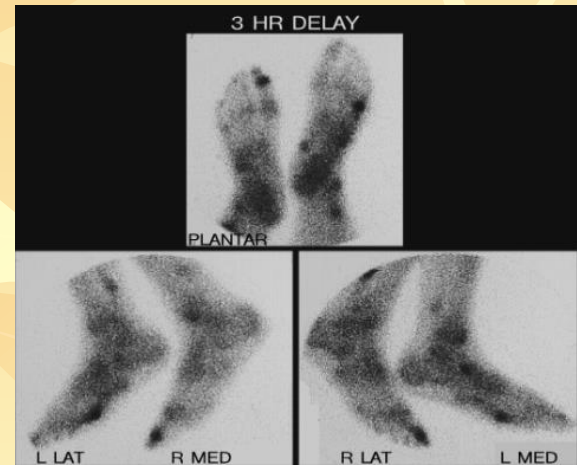
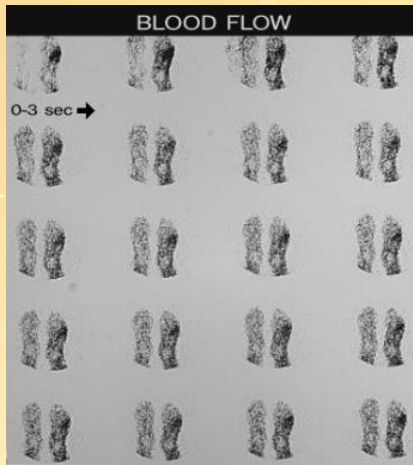
VERTEBRAL BODY ABSCESS (^{111}In -WBC scan)



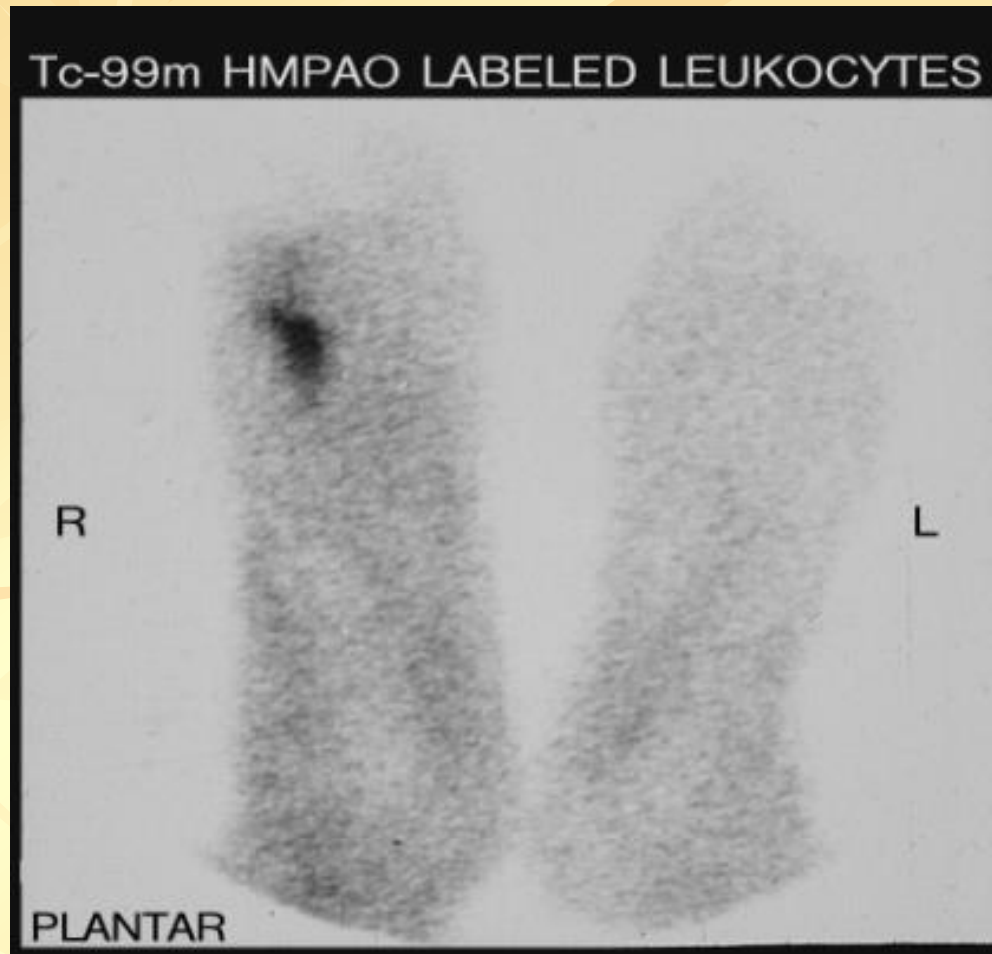
Osteomyelitis of Rt. Sup. Pubic Ramus



DIABETIC FOOT (osteomyelitis)



111In-WBC Scan

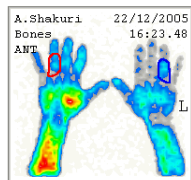


ACUTE OSTEOMYELITIS (Lt.4th phalange)

NAME A. Shakuri BIRTH DATE 81.0 y STUDY ID
 DOCTOR ORGAN Bones VIEW ANT
 STUDY DATE 22/12/2005 RADIONUCLID Tc-99m ACTIVITY 25.0 MBq

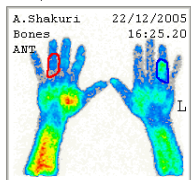
Lt: 0 Ut: 100
 Lt: 0 Ut: 100

Perfusion Phase



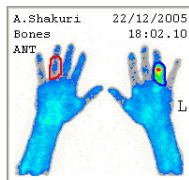
Phase duration : 60 sec.

Bloodpool Phase



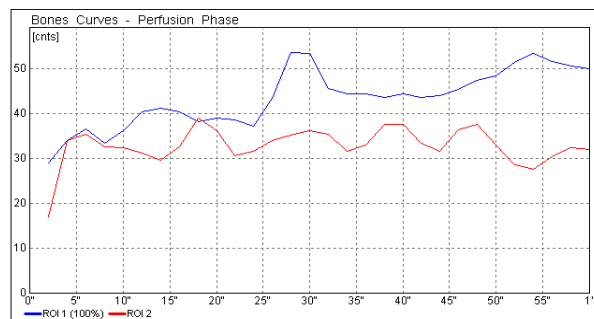
Frame duration : 150 sec.

Skeletal Phase



Frame duration : 450 sec.

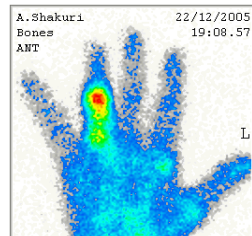
ROI 1 (100%)		ROI 2	
ROI 1 (100%)/ROI 2			
Bloodpool Ratio		2.19	
Skeletal Ratio		4.58	



NAME A. Shakuri BIRTH DATE 0.0 y STUDY ID
 DOCTOR ORGAN Bones VIEW ANT
 STUDY DATE 22/12/2005 RADIONUCLID Tc-99m ACTIVITY 25.0 MBq

Lt: 0 Ut: 100

Skeletal Phase

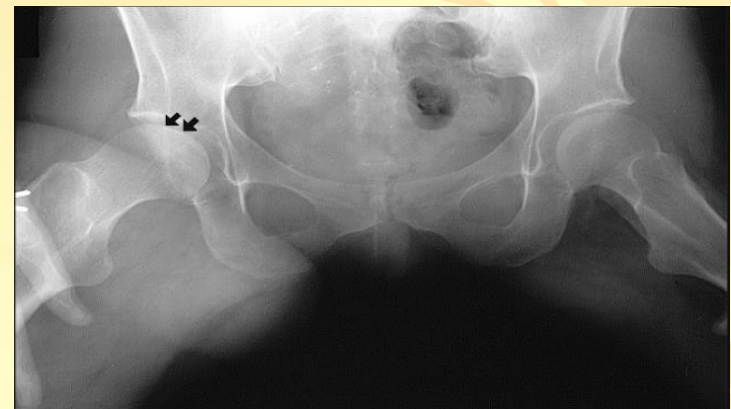
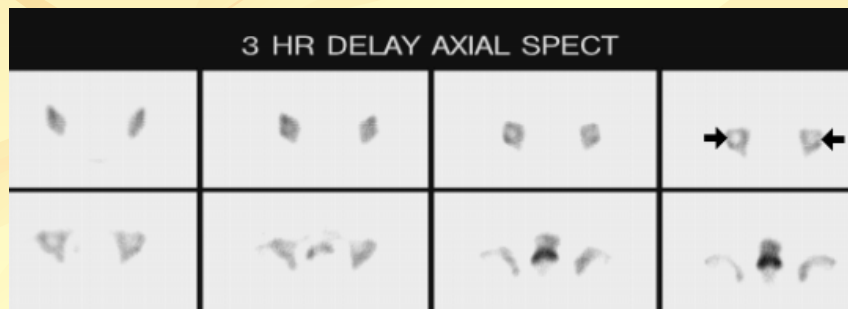
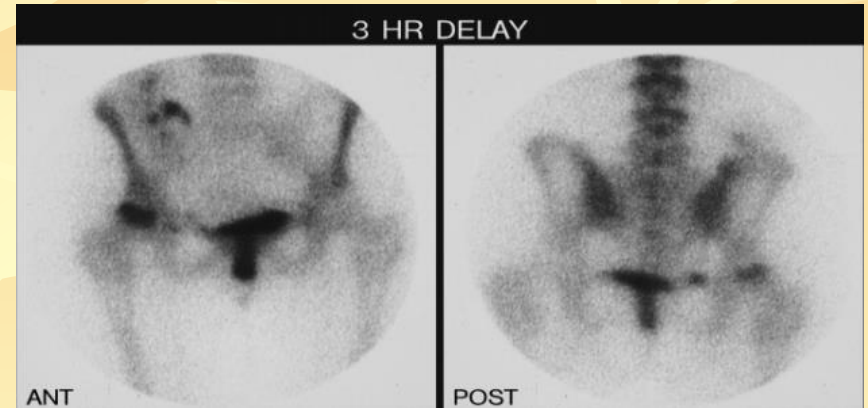
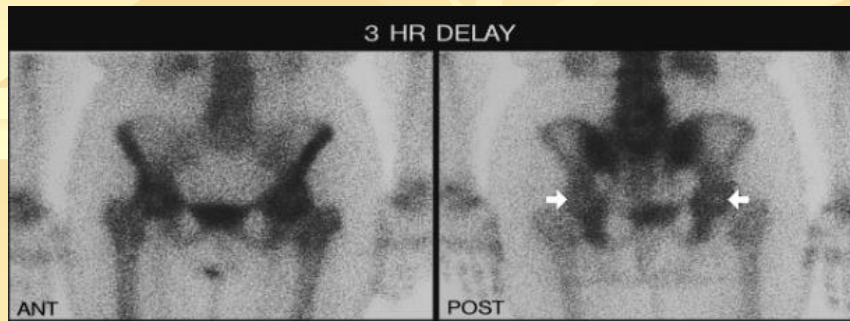


Frame duration : 425 sec.

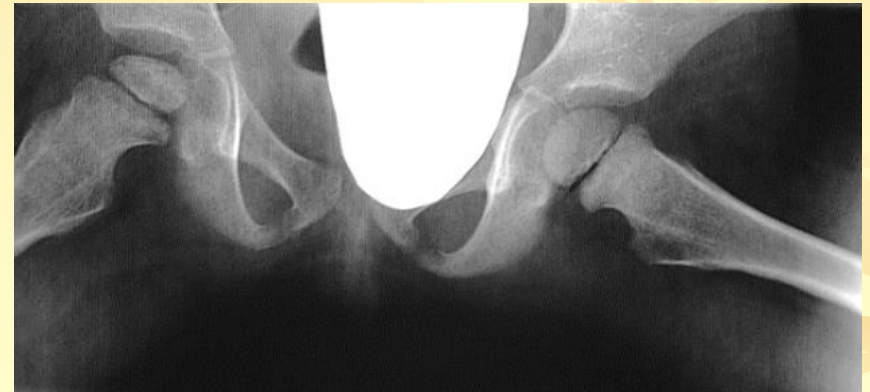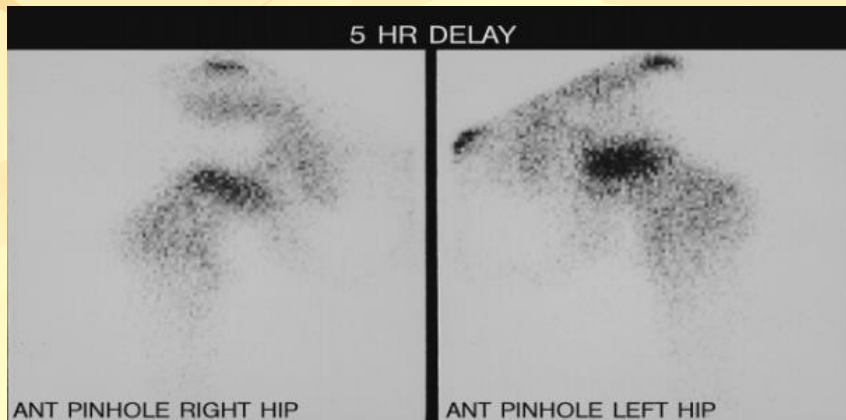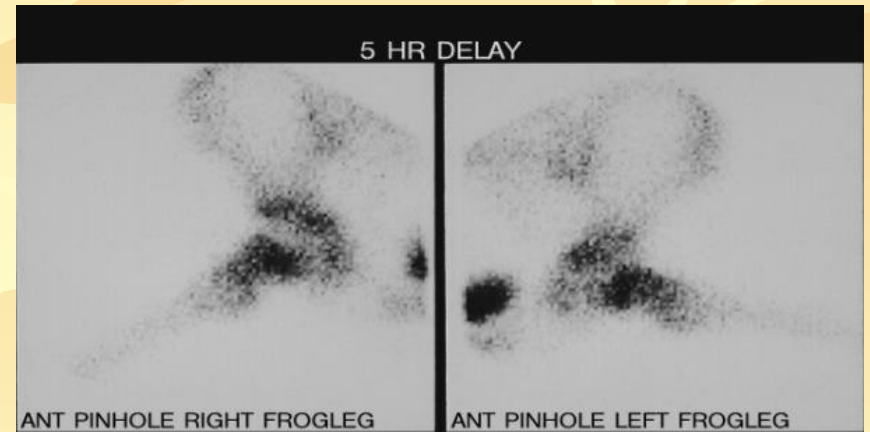
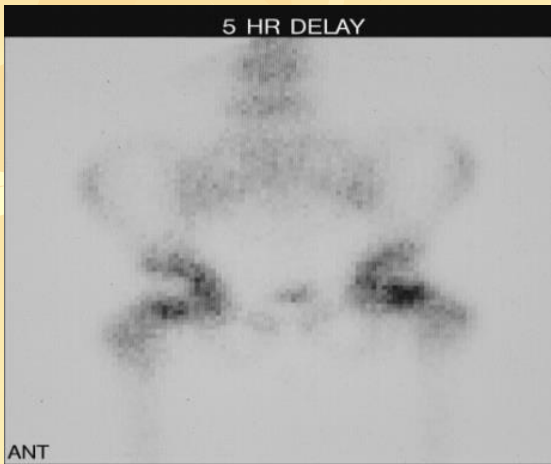ROI 1 (100%)		ROI 2	
ROI 1 (100%)/ROI 2			
Skeletal Ratio		0.00	



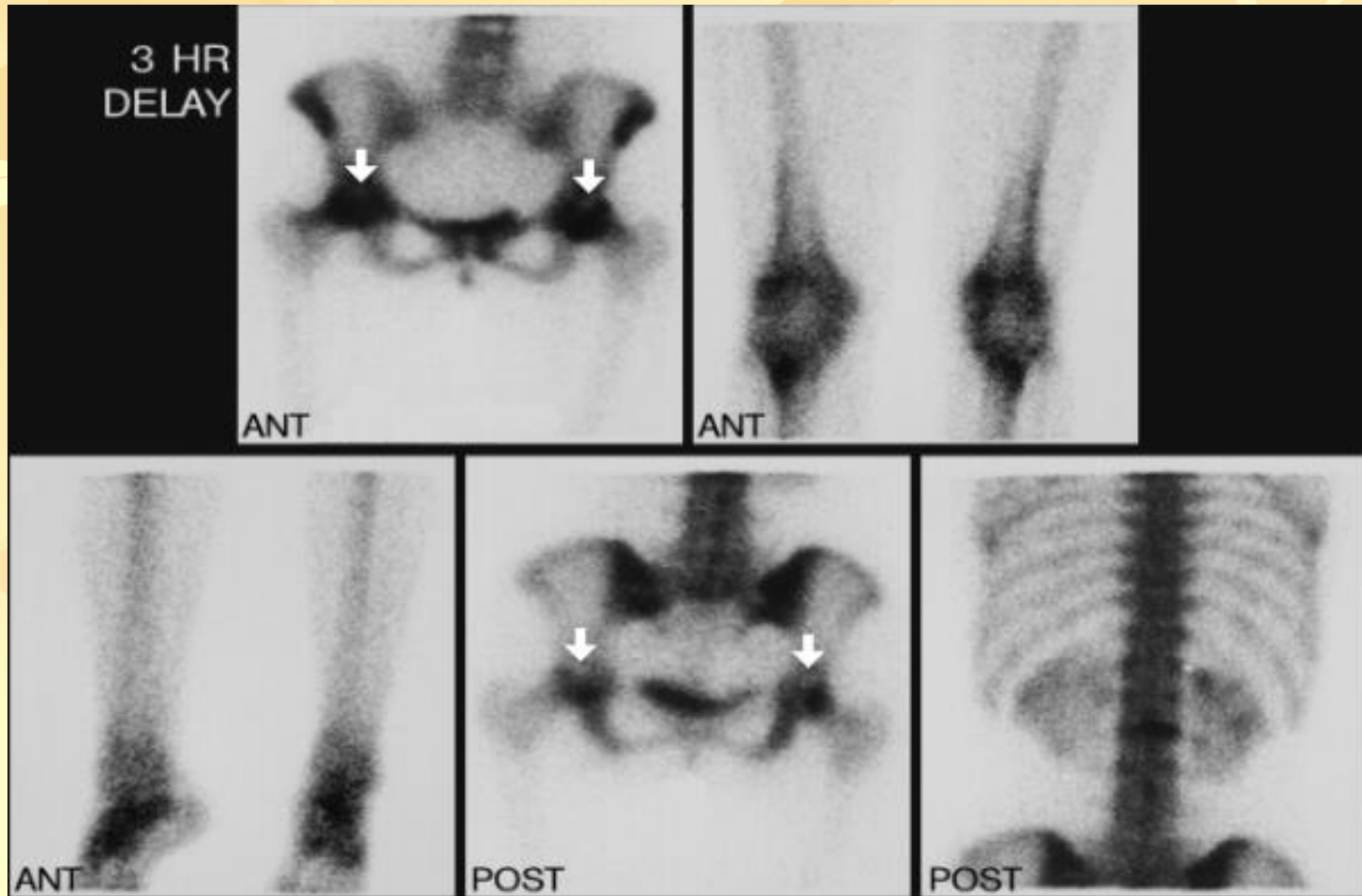
AVN of the Femoral Heads (steroid therapy)



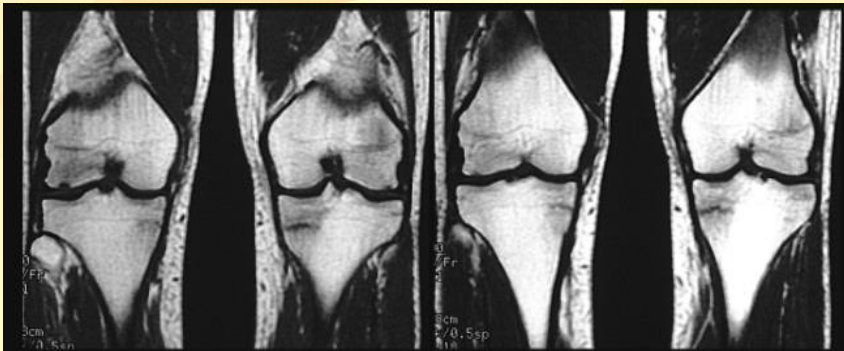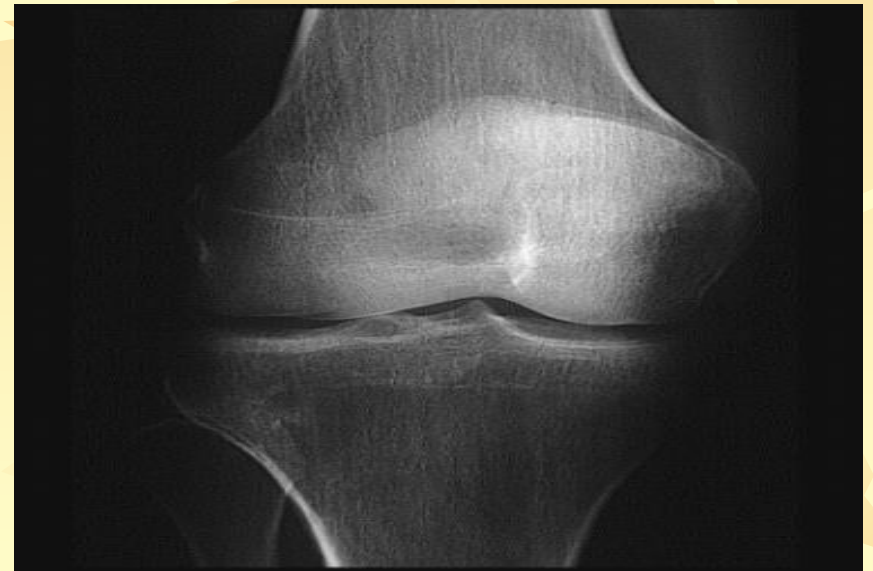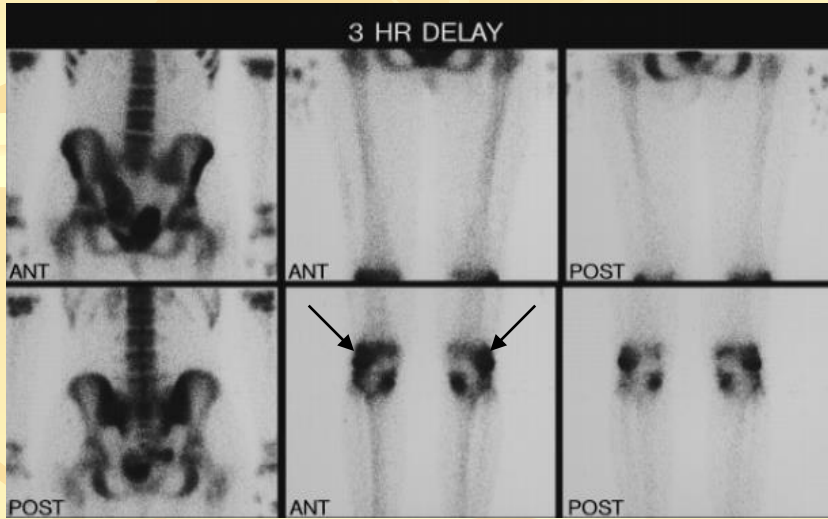
LEGG-CALVE-PERTHES DISEASE(Rt.)



AVN(SLE with Long Term Steroid Therapy)



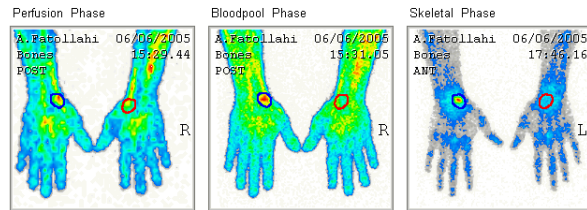
AVN (Post Renal Transplant)



SCAPHOID'S AVN (Healing Phase)

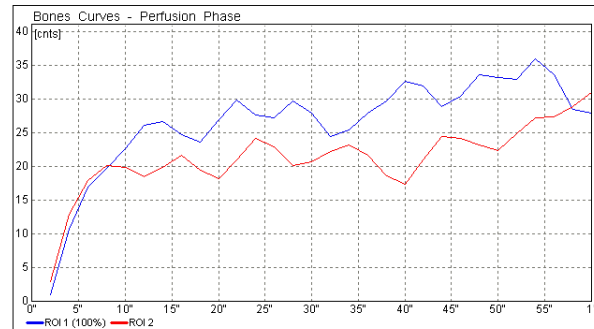
NAME A.Fatollahi BIRTH DATE 0.0 y STUDY ID
 DOCTOR Dr.Mouria ORGAN Bones VIEW POST
 STUDY DATE 06/06/2005 RADIONUCLID Tc-99m ACTIVITY 25.0 MBq

Lt: 0 Ut: 100
 Lt: 0 Ut: 100



Phase duration : 60 sec. Frame duration : 244 sec. Frame duration : 221 sec.

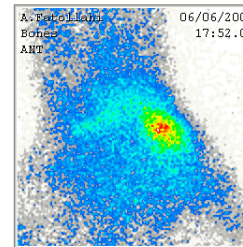
ROI 1 (100%)	ROI 2
ROI 1 (100%)/ROI 2	
Bloodpool Ratio	1.53
Skeletal Ratio	1.74



NAME A.Fatollahi BIRTH DATE 0.0 y STUDY ID
 DOCTOR ORGAN Bones VIEW ANT
 STUDY DATE 06/06/2005 RADIONUCLID Tc-99m ACTIVITY 25.0 MBq

Lt: 0 Ut: 83

Skeletal Phase

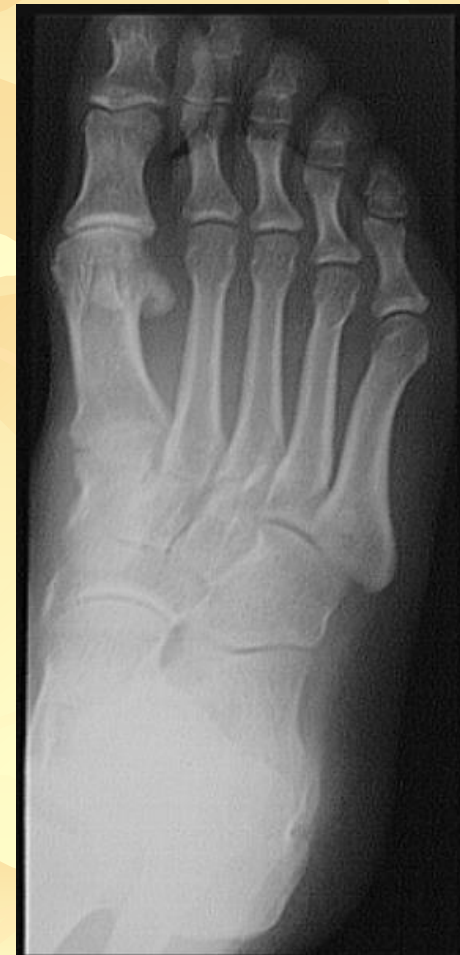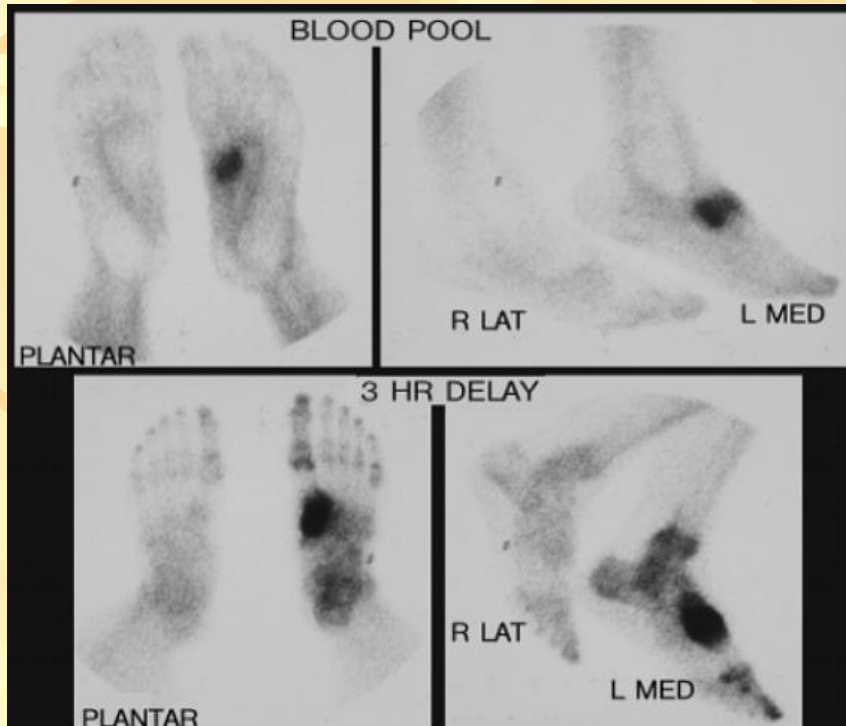


Frame duration : 683 sec.

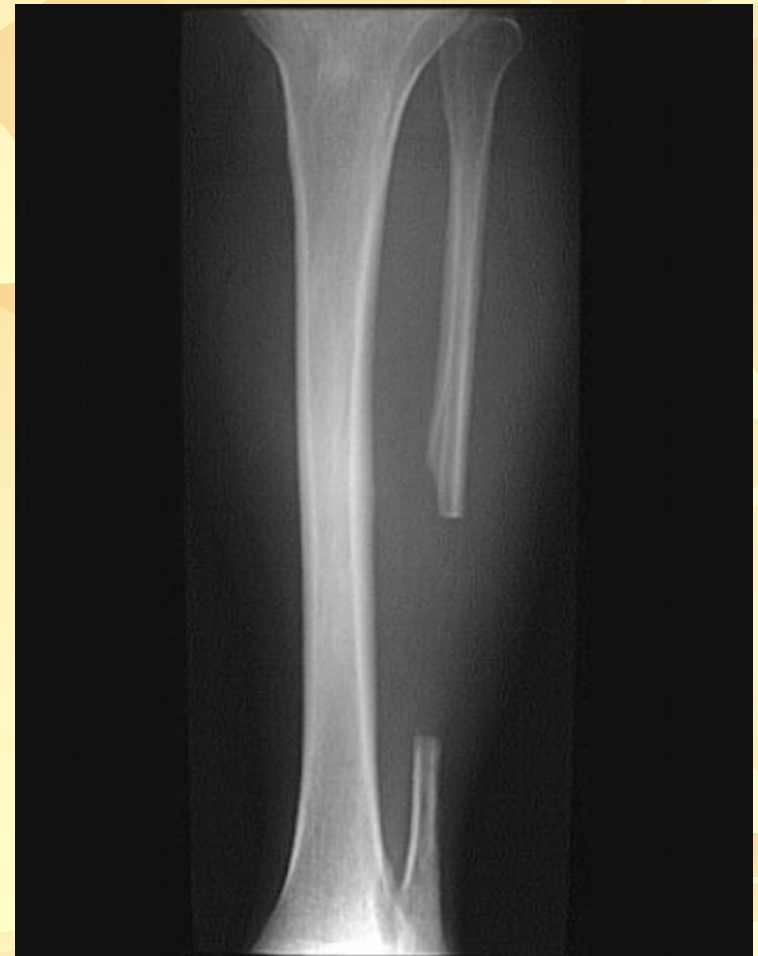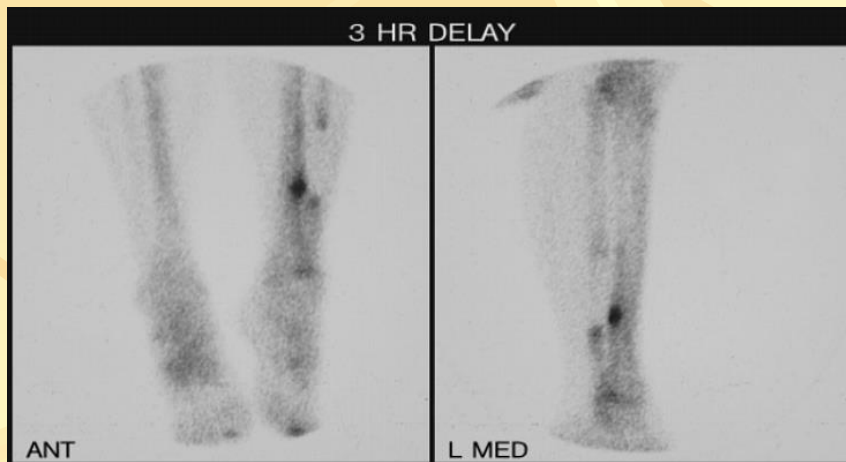
ROI 1 (100%)	ROI 2
ROI 1 (100%)/ROI 2	
Skeletal Ratio	0.00



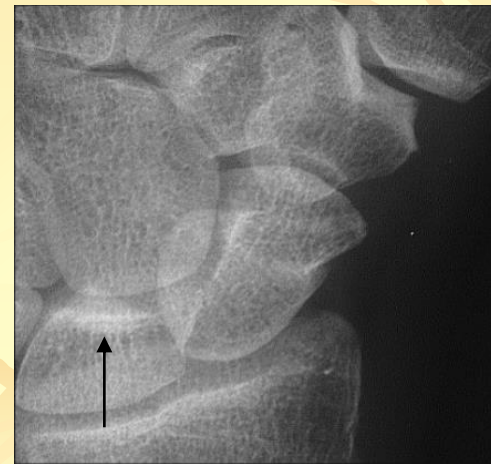
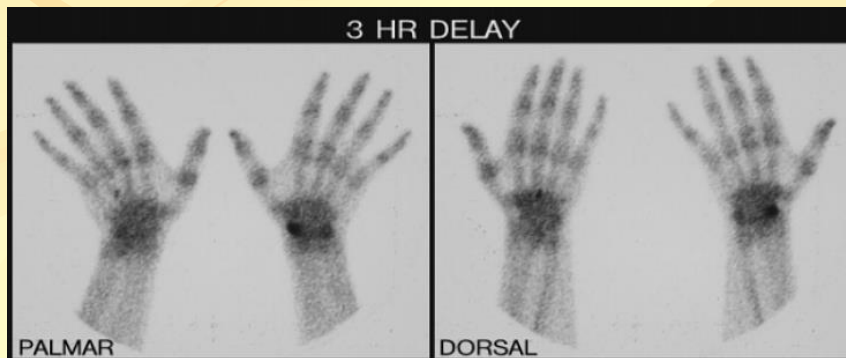
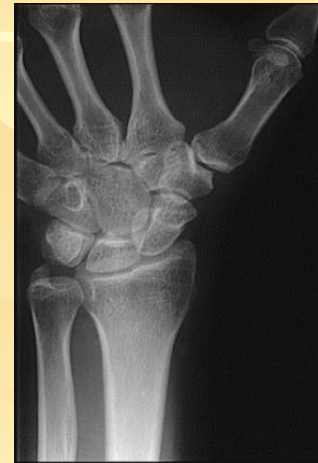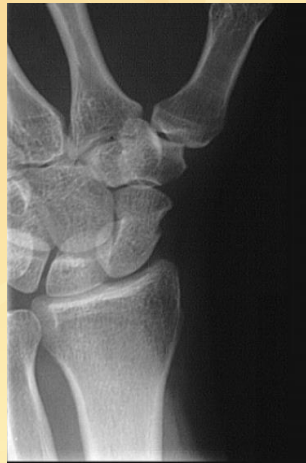STRESS FRACTURE (Base of the 1th metatarsal)



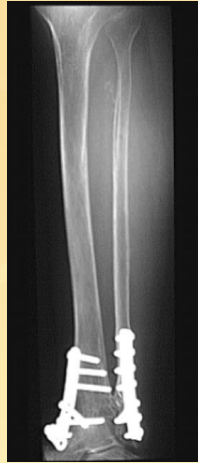STRESS Fr. of the Lt. Tibia (previously resected fibula)



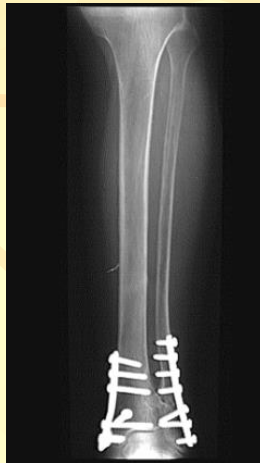ACUTE Lt.NAVICULAR Fx. (normal early X-Ray)



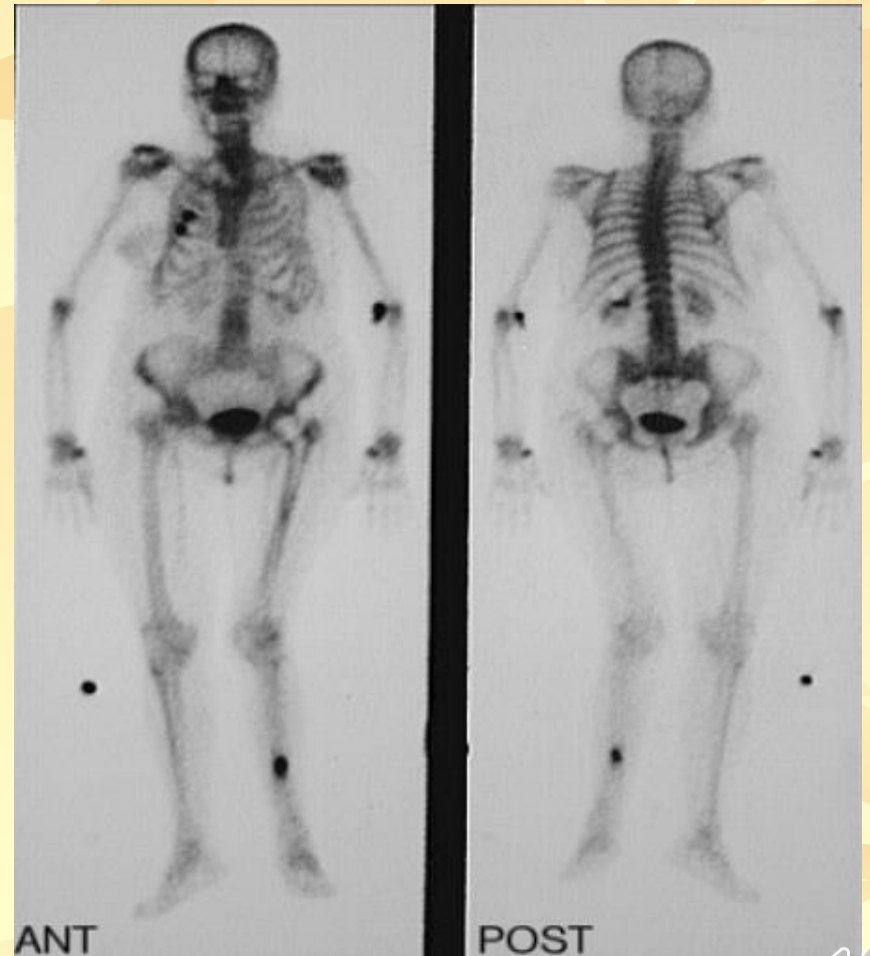Stress Fracture of Lt. Tibia



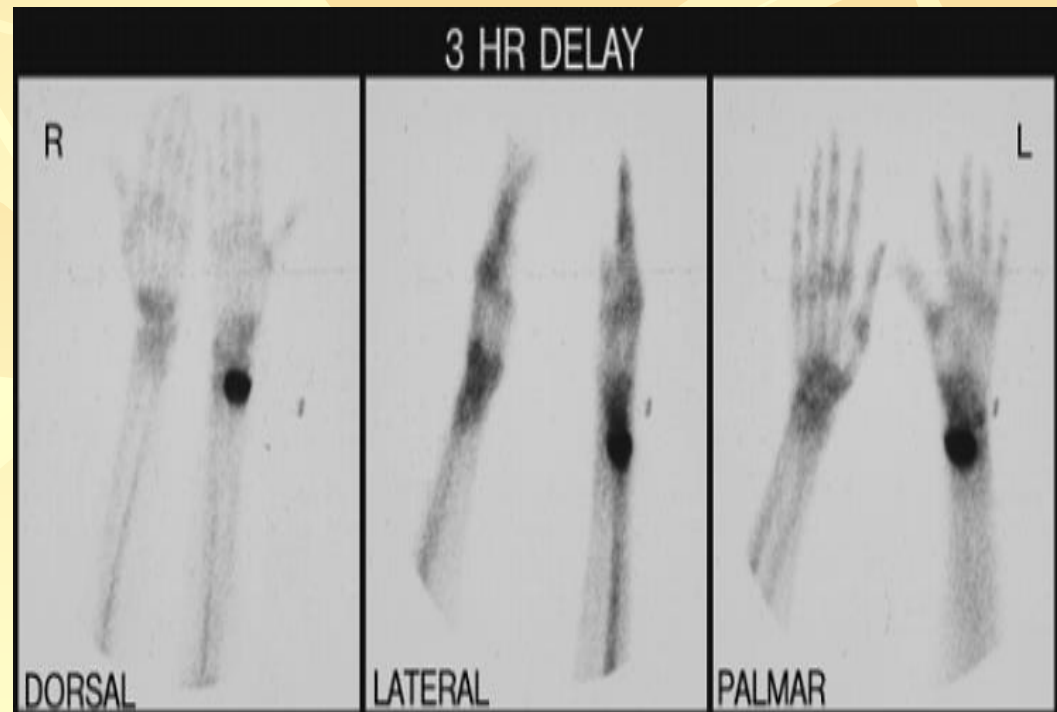
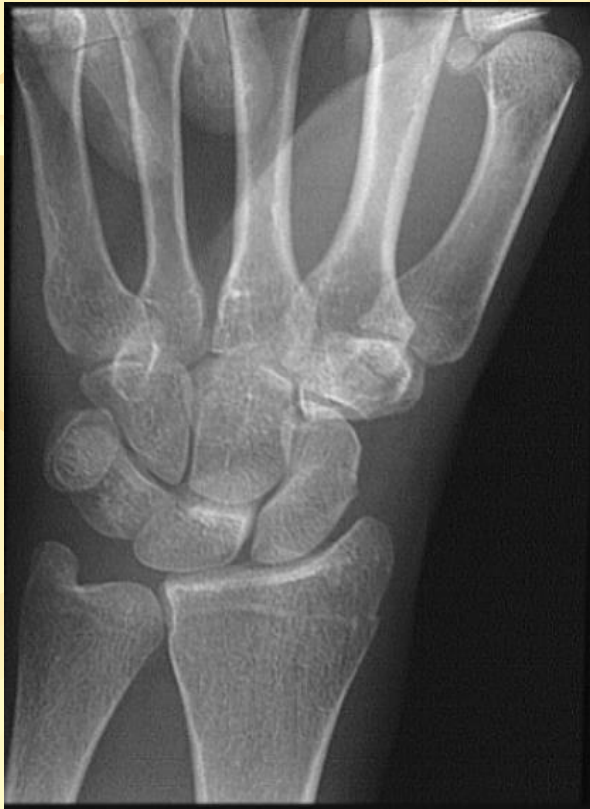One mo. before scan



One mo. after scan



Occult Fracture of Distal Lt. Radius (post injury)



Multiple Trauma with Vertebral Body Compression Fr.

